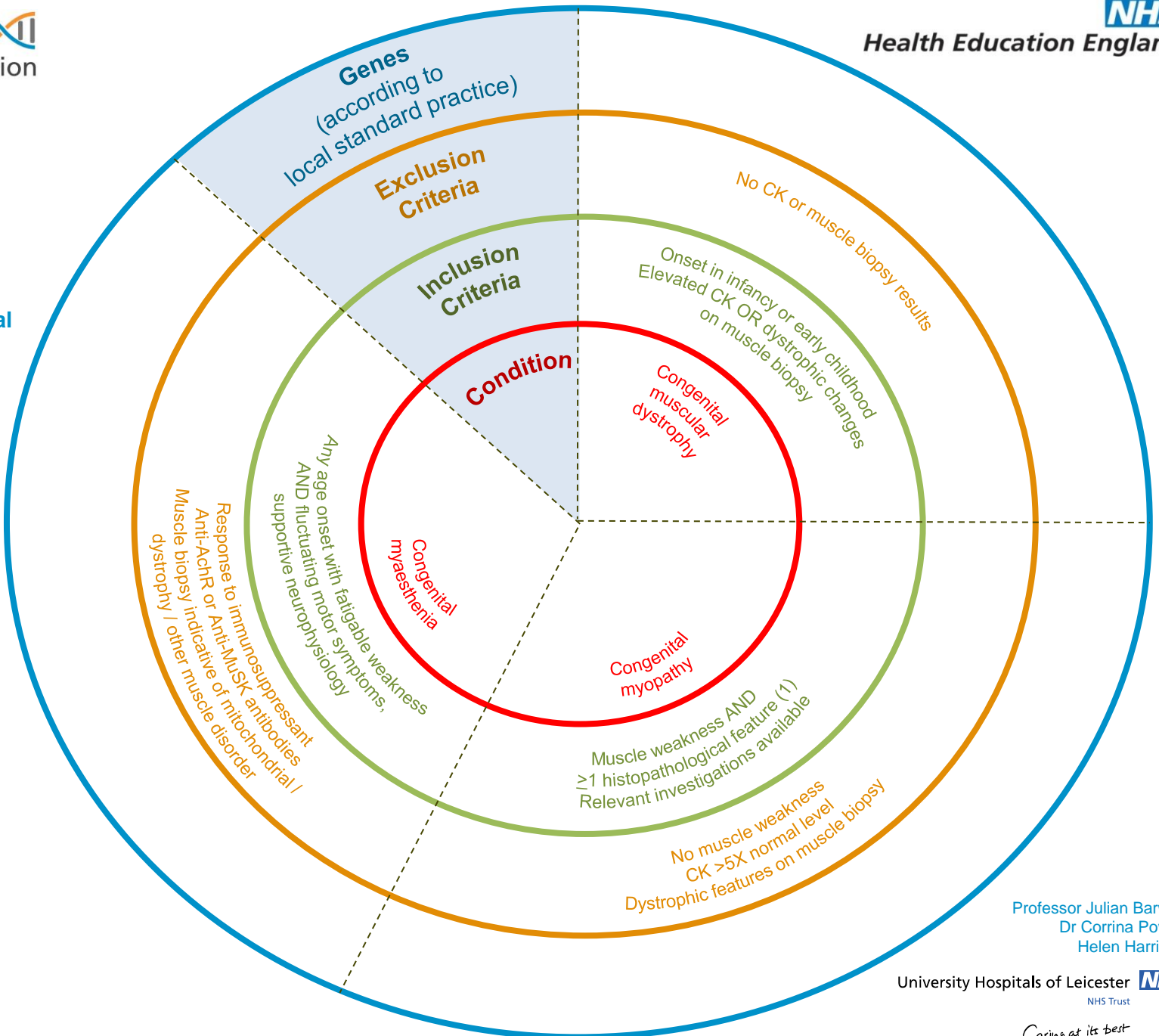




- (1)
- Type 1 predominance or uniformity
 - Congenital fibre type disproportion
 - Central cores
 - Multi-minicores
 - Nemaline rods
 - Central nuclei



Professor Julian Barwell
Dr Corrina Powell
Helen Harrison

University Hospitals of Leicester NHS Trust

Caring at its best